



## CASE REPORT

# Ascites associated with Congestive Heart failure in a police dog (K 9) (Diagnosis and management)

Kamal M Alsaad<sup>1\*</sup>, Abdulbari A Alfaris<sup>2</sup>, Mohanad H Lafta<sup>1</sup>

<sup>1</sup>Department of internal and preventive medicine, College of Veterinary Medicine, University of Basrah, Iraq.

<sup>2</sup>Department of surgery and obstetrics, College of Veterinary Medicine, University of Basrah, Iraq.

### Abstract

A male, Mullinoise breed K9 dog, 23 kg weight and of 5.7 years old, had been brought to the Consultant Veterinary Teaching Hospital, College of Veterinary Medicine, University of Basrah, Iraq, with a patient history of acute illness of 1-4 days' duration, Dyspnea with open-mouth breathing sometimes, lethargy, reduced food intake, an obvious distended abdomen developed gradually, reduced exercise tolerance, coughing, and occasionally weight loss with fainting only at exercise sometimes. In addition to a history of deworming and vaccination had been applied previously. Clinical examination revealed respiratory distress, severe abdominal distension, lethargy, pale gum and mucous membrane, Harsh lung sound with pulmonary crackles are typically present on the auscultation of the chest, However, a loud murmur is indicated on auscultation of the heart area, Furthermore, slight hepatomegaly, Distended jugular vein and a weak femoral arterial pulse were also detected on clinical palpation of diseased dog. Congestive heart failure was suspect, according to the clinical presentation, Hematological and biochemical results, in addition to Ultrasonography diagnosis.

### Introduction

A different and multiple causes had been indicated to describe ascites in dogs, Disorders of different body organs like liver and kidney, Hypoproteinemia and heart failure could be the main and a common cause associated with ascites in dogs [1, 2]. However, Ascites may indicate a serious condition that needed an immediate medical and may be rationale treatment, which must depend on proper diagnosis [3, 4]. Congestive heart failure (CHF) defined as the presence of accumulated fluids in the lungs (as a pulmonary edema), in the pleural space (as a pleural effusion), in the abdominal cavity (as ascites), or pericardial sac (as a pericardial effusion) due to cardiac dysfunctions, Moreover, in congestive heart failure, The heart cannot deliver a sufficient amount of blood to its own body which might cause by failure of the right side of the heart, or the left side or both of them [5]. Accumulation of cardiogenic fluid only occurs in dogs with elevated diastolic, ventricular, and /or atrial filling pressures, Therefore, The Left-sided Congestive heart failure might developed in dogs with high left heart filling pressures which leads to pulmonary edema with or without small volume of pleural effusion, On the other hand, The Right-sided Congestive heart failure will occur in dogs when the right heart filling pressures will elevated and is reflected as ascites with or without pleural effusion, Nevertheless, Most dogs with large volume pleural effusion might have biventricular heart failure with elevated right and left heart filling pressures [6].

The most important and common causes of congestive heart failure are valvular disease (congenital or acquired), Dilated cardiopathy, endocardiosis, mitral and tricuspid regurgitation,

congenital heart disease, Heart worms, Increase blood pressure, Tumors and even pregnancy in females [7]. Furthermore, Erling and Mazzaferro 2008 [5], added that, the probable cause such as a deficiency of vitamin E and / or selenium also might play good rule in the occurrence of myocardial dystrophy, Moreover, heart failure can be primary or secondary to other diseases, such as atherosclerosis, chronic nephritis, liver disease and even obesity [8]. At the early stage of the condition, dogs show no clear clinical signs, whereas, when the disease progresses, diseased animals might show, coughing, difficult or rapid respiration, lack of performance and fast tiredness, episodes of faint, gray or blue gums, abdominal distension, collapse and finally death [5]. The present case report, illustrated the diagnosis of congestive heart failure associated with ascites and its management in a male, Mullinoise breed, police dog.

### Case history and present clinical and laboratory examinations of the present case

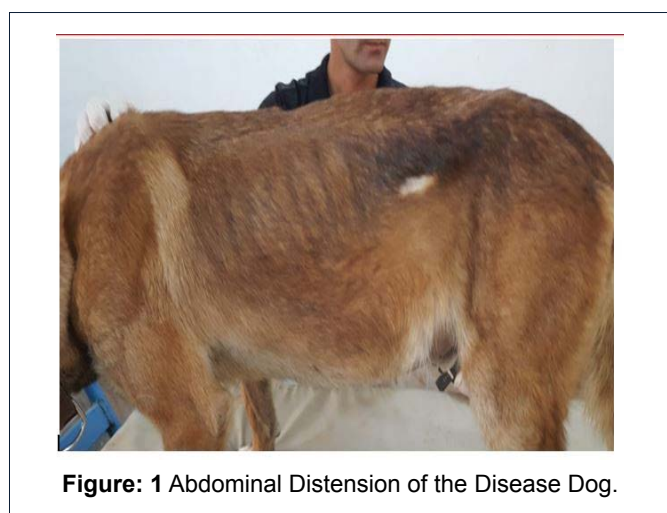A male, Mullinoise breed a police (K9) dog, 23 kg weight and of 5.7 years old, had been brought to the Consultant Veterinary Teaching Hospital, College of Veterinary Medicine, University of Basrah, Iraq, with a patient history of acute illness of 1-4 days' duration, dyspnea with open-mouth breathing sometimes, lethargy, reduced food intake, an obvious distended abdomen

**Correspondence to:** Kamal M. Alsaad, Department of internal and preventive medicine, College of Veterinary Medicine, University of Basrah, Iraq, Email: kamalsad58[AT]yahoo[DOT]com

**Received:** April 16, 2018; **Accepted:** April 17, 2018; **Published:** April 21, 2018

developed gradually, reduced exercise tolerance, coughing, and occasionally weight loss with fainting only at exercise sometimes. In addition to a history of deworming and vaccination had been applied previously. Clinical examination revealed respiratory distress, severe abdominal distension, (Figure 1), lethargy, pale gum and mucous membrane, Harsh lung sound with pulmonary crackles are typically present on the auscultation of the chest, However, a loud murmur is indicated on auscultation of the heart area, Slight hepatomegaly, Distended jugular vein. A weak femoral arterial pulse was also detected on clinical palpation of the diseased dog.

Vital signs of the dog, (Table 1) show that, Body temperature is 38.4 C. Heart rate of 105/ min, respiratory rate 37/ min. Capillary refill time is 5/Sec. (Table 1). Blood was collected for a complete blood analysis (On an automatic full digital cell counter, Beckman, USA) and the results are shown in (Table 2). Since



**Figure 1:** Abdominal Distension of the Disease Dog.

Parameters	Diseased dog	Normal reference*
Body temperature C	38.4	37.5-39.2
Heart rate /min	105	70-120
Respiratory rate/ min	37	15-30
Capillary refill time/ Sec	5	2

**Table 1:** The vital signs of the diseased dog [9].

Parameters	Diseased dog	Normal reference*
TRBc x 10 <sup>6</sup>	4.5	4.8-9.3
Hb g/dl	8.5	12.1-20.3
PCV %	42	37-55
MCV / fl	93.33	58-79
MCH / pg	18.4	18.2-18.8
MCHC /g/dl	20.23	30-38
TLC x 10 <sup>3</sup>	8	4.0-15.5
Neutrophils %	57	66-77
Lymphocyte %	30	12-30
Eosinophils %	3	2-12
Monocytes %	10	3-10
Basophiles %	0	0-1
ESR mm/h %	33	0.5-0.7
Total platelet counts x 10 <sup>3</sup>	110	170-400

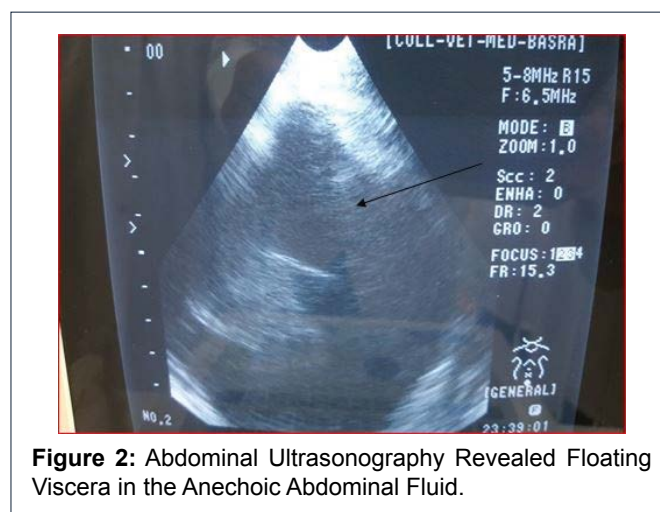
**Table 2:** Complete blood analysis of the disease dog [10].

it seems that the disease dog have a Macrocytic Hypochromic type of anemia, with high value of erythrocyte sedimentation rate, However the total platelet count was low. Serum was prepared for biochemical analysis and the results indicated low values of total protein (Hypoproteinemia). Increase value of Troponin I, Hcy, CpK-MB, and LDH, However, Triglyceride and total Cholesterol values was also high. (Table 3).

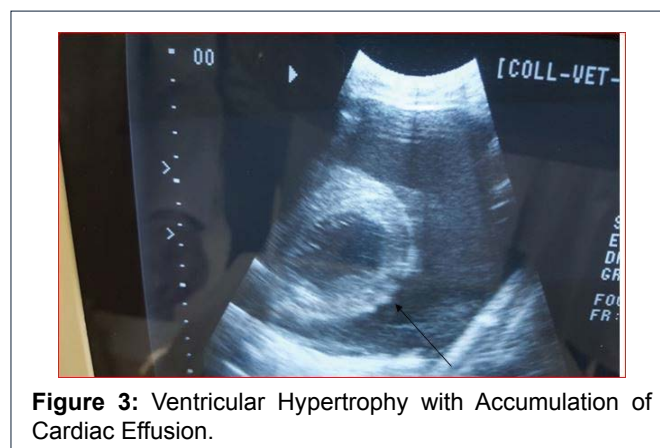
Furthermore, the dog was subjected to ultrasound examination and Abdominal ultrasonography revealed floating viscera in the anechoic abdominal fluid, Figure 2, Moreover, No abnormal echogenicity was noticed with the abdominal organs such as kidney, spleen, and urinary bladder, However slight hepatomegaly was specified. Furthermore, an expectance of ventricular hypertrophy with accumulation of cardiac effusion was also detected. Figure 3. Moreover, fecal examination reveals negative for endoparasite and intestinal protozoan infestation.

Parameters	Diseased dog	Normal reference*
Total protein gm/dl	2.9	5.0-7.4
Cardiac troponin I (cTnI) ng/ml	13	0.3-0.7
Homocystein (Hcy) μmol/L	1.4	67.10±31.92
CpK-MB U/l	77	50.64±24.48
LDH U/l	16	10.06±3.05
Triglycerides mg/dL	210	29-200
Cholesterol mg/dl	440	92-324

**Table 3:** Biochemical analysis of diseased dog [10].



**Figure 2:** Abdominal Ultrasonography Revealed Floating Viscera in the Anechoic Abdominal Fluid.



**Figure 3:** Ventricular Hypertrophy with Accumulation of Cardiac Effusion.

## Treatment and Management

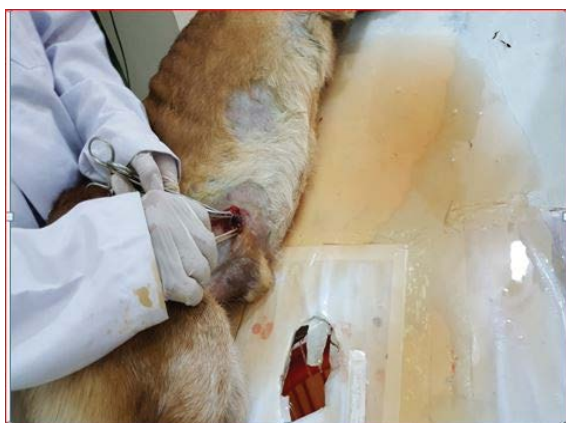According to the clinical and laboratory results, diseased dog with ascites and cardiac effusion was suspected to have congestive heart failure and the clinical case was treated with the evacuation of the abdominal fluid (therapeutic paracentesis) via laboratory, Figure 4. Since, A surgical incision of 2cm length are inducing after local analgesia for drainage of the abdominal fluid. The surgical wound was sutured using catgut for muscles and silk for the skin.

Moreover, A medical treatment has been prescribed includes (Nebivolol 1mg daily orally (A Beta-blockers and blood pressure regulator), Ringer's solution I.V infusion, Furosemide 4mg I.M for 5 days.

After 2-3 days of giving therapy, slight improvement in physical activity, appetite and general health condition observed, however, abdominal distension was disappeared. Figure 5.

## Discussion

The clinical manifestations beside the hematological and biochemical results of the present case were agreed with others [5, 8, 11]. It had been mentioned that in many animals



**Figure 4:** Evacuation of the Abdominal Fluid via Laboratory.



**Figure 5:** Slight Improvement of the Dog after 2-3 Days.

with a long history of mitral valve insufficiency, pulmonary hypertension and right side heart failure might be developed and the right side heart failure might be occurred as secondary due to persistent elevation of left atrial and pulmonary venous pressures, Furthermore, As the wall of right ventricle is thinner and more compliant as compared to the left ventricle, it can be increased in volume, However, this caused a decreased in stroke volume of the heart. As a result of elevated right atrial pressure, ascites, pleural, pericardial effusion, hepatomegaly and even splenomegaly might be developed, However, The most common manifestations of right heart failure are respiratory distress, abdominal distension due to ascites, hepato or splenomegaly [12, 13]. Moreover, Saunders and Gordon, 2015 [8], was also agreed and added that, Congestive heart failure will expected, when the heart is no longer able to compensate, as systemic congestion may result from the impaired blood flow returning to the right heart from the body and the blood will backs up and fluid leaks through the vessels into other parts of the body, resulting to ascites, pleural and pericardial effusion. Another idea that had added by [3, 4], As, In congestive heart failure cases that develop slowly, the collapse of blood pressure and the installing of a cardiogenic attack are of the most possible outcomes, in addition, A dog's myocardium tries and managing to Adjusts to the new situation by using different restoring mechanisms, such as tachycardia, tachypnea that means rapid contractions of the heart, vasoconstriction and by increasing its volume, Moreover, After a while the poor irrigation of the internal organs will resulting in pulmonary edema, liver failure and passive venal congestion.

Results of the present case show increase values of cardiac enzymes which, confirmed the diagnosis of the congestive heart failure of the dog, Since the cardiac enzymes was considered as a good biomarkers for evaluation of myocardial problems, Because they have nearly absolute myocardial tissue specificity and higher sensitivity than others [14,15].

## References

1. Ettinger SJ, Feldman EC (2005) Text book of Veterinary Internal Medicine: Disease of Dog and Cat (6<sup>th</sup> edn). In: WB Saunders (Ed.), Philadelphia, USA, pp. 137-145. [View Article]
2. Dabas VS, Suthar DN, Chaudhari CF, Modi LC, Vihol PD (2011) Ascites of splenic origin in a mongrel female dog-a case report. *Vet World*. 4: 376-377. [View Article]
3. Atkins C, Bonagura J, Ettinger S, Fox P, Gordon S, Haggstrom J, et al. (2009) Guidelines for the diagnosis and treatment of canine chronic valvular heart disease. *Vet Int Med* 23:1142-1150. [View Article]
4. Borgarelli M, Haggstrom J (2010) Canine degenerative myxomatous mitral valve disease: natural history, clinical presentation and therapy. *Vet. Clin North Am Small Anim Pract* 40: 651-663. [View Article]
5. Erling P, Mazzaferro EM (2008) Left-sided congestive heart failure in dogs: Pathophysiology and diagnosis. *Compend Contin Educ Vet* 30: 79-90. [View Article]
6. Tarn AC, Lapworth R (2010) Biochemical analysis of ascetic (peritoneal) fluid: what should we measure? *Ann Clinic Biochem* 47: 397-407. [View Article]

7. Buchanan JW (1997) Chronic valvular disease (endocardiosis) in dogs. *Adv Vet Sci Comp Med* 21: 75-106. [[View Article](#)]
8. Saunders AB, Gordon SG (2015) Heart Failure in Dogs. *Today's Vet Prac* pp. 23-28. [[View Article](#)]
9. Kenrose S (2012) Addison's disease in Dogs. Barnes & Noble®, USA. [[View Article](#)]
10. Kerr MG (2008) Veterinary Laboratory Medicine: Clinical Biochemistry and Haematology, (2<sup>nd</sup> edn). Wiley, USA. [[View Article](#)]
11. Sisson D, Kittleson MD (1999) Management of heart failure: principles of treatment, therapeutic strategies and pharmacology. In: Fox PR, et al. (Eds.), Textbook of Canine and Feline Cardiology, Philadelphia, USA, pp. 216-250. [[View Article](#)]
12. Mazzaferro EM (2005) Emergency management of congestive heart failure. *Vet Med* pp. 734-741. [[View Article](#)]
13. Borgarelli M, Buchanan JW (2012) Historical review, epidemiology and natural history of degenerative mitral valve disease. *J Vet Cardiol* 14: 93-101. [[View Article](#)]
14. Haggstrom J (2010) Myxomatous mitral valve disease. In: Luis Fuentes V et al. (Eds.), BSAVA Manual of Canine and Feline Cardiorespiratory Medicine (2<sup>nd</sup> edn), British Small Animal Veterinary Association, Gloucester, UK, pp. 186-194. [[View Article](#)]
15. Oyama MA, Sisson DD (2004) Cardiac troponin-I in dogs with cardiac disease. *J Vet Intern Med* 18: 831-839. [[View Article](#)]

**Citation:** Alsaad KM, Alfaris AA, Lafta MH (2018) Ascites associated with Congestive Heart failure in a police dog (K 9) (Diagnosis and management). *Vet Sci Med* 1: 001-004.

**Copyright:** © 2018 Alsaad KM, et al. This is an open-access article distributed under the terms of the Creative Commons Attribution License, which permits unrestricted use, distribution, and reproduction in any medium, provided the original author and source are credited.

---