

CASE REPORT

Orofacial Granulomatosa: A Case for Interprofessional Collaboration

Blasé P Brown*

Director of Small Group Learning, UIC College of Dentistry, Chicago, USA

Introduction

Within the goals of interprofessional collaboration, the value of determining a correct diagnosis among participating healthcare providers is consistent with improving patient experiences and reducing healthcare costs. An atypical presentation of signs and symptoms of a disease entity can create a diagnostic challenge for healthcare providers that often require patients to navigate the healthcare system resulting in treatment delays. [1-4] the patient problem presented in this current case demonstrates the need for interprofessional collaboration among providers when facing a diagnostic challenge.

Case Description

A 59 year old female patient [Figure 1] presented to a primary care clinic with the chief complaint of upper lip swelling,

PATIENT
Female Caucasian DOB: 07/30/1957 (59)
CHIEF COMPLAINT/CONCERN
"Upper lip and Facial Swelling"
BACKGROUND AND/OR PATIENT HISTORY
Penicillin allergy Current medications: Estradiol 2 mg Lorazepam 1 mg Paroxetine 37.5 mg Special Education High School Teacher
CURRENT FINDINGS
Diagnosis: Swelling, mass, or lump on face Temp: 37°C BP: 135/80

Figure 1: Abbreviated patient history and diagnostic information.

which had been present for three days. A diagnosis of Herpes Labialis was made and Valtrex 500 mg prescribed. Four days later, the patient returned to the primary care clinic when the swelling spread to the left side of her face. No additional testing, diagnoses, or treatment was rendered at that time. Following an additional four days, the patient returned to the primary care clinic when the swelling had spread to the right side of her face. A bacterial infection was suspected and Clindamycin 300 mg prescribed. A blood specimen was drawn with lab order for a CBC with Differential/Platelet; Complete metabolic panel; TSH; Antinuclear Antibodies Direct; C-Reactive Protein, Quant. [Table 1].

On the following day, she then presented to the Emergency Department of a local hospital with the complaint of facial swelling. The swelling, which began in her upper lip two weeks earlier, had now spread to the left and right cheeks, just below her eyes, encompassing most of her mid-face [Figure 2]. Vital signs were within normal limits, with a slight increase in systolic and diastolic blood pressure readings. The patient had not experienced pain. The patient had no remarkable history of trauma or other environmental occurrence. The emergency room (ER) physician did not make a differential diagnosis of the facial swelling. The ER medical staff prescribed the following diagnostic tests, medication, and follow-up care:

Additional Procedure and tests performed during the Emergency Department visit:

C3 and C4

Positive Lab Results	Result	Reference Interval
WBC	11.8 x 10 ³ /μl	3.4-10.8 x 10 ³ /μl
Platelets	389 x 10 ³ /μl	150-379 x 10 ³ /μl
Neutrophils	9.2 x 10 ³ /μl	1.4-7.0 x 10 ³ /μl
Glucose, Serum	102 mg/dl	65-99 mg/dl

Table 1: Laboratory results from Day 4/Primary Care Provider visit. Positive results above the Reference Intervals, particularly WBC and Neutrophil, did not inform provider diagnosis.

Correspondence to: Blasé P Brown, Director of Small Group Learning, UIC College of Dentistry, Chicago, USA, Email: bpbrown[at]uic[DOT]edu

Received: June 25, 2018; **Accepted:** June 27, 2018; **Published:** June 29, 2018

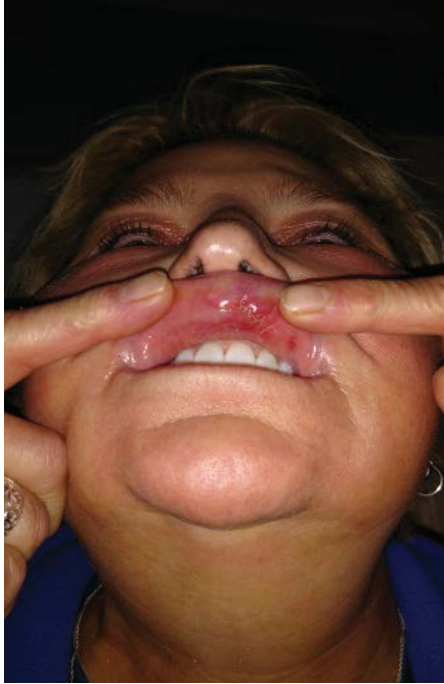

Figure 3: Upper lip incisional biopsy.

consulted with an ENT (MD). A head and neck **Maxillofacial CT** scan with intravenous contrast was ordered and completed with the following findings:

Facial bones: No fracture or focal osseous abnormality identified.

Facial soft tissues: There are soft tissues swelling with abnormal attenuation noted over the malar regions bilaterally involving the anterior buccal space. This extends superiorly to the level below the inferior margin of the orbit. There is abnormal subcutaneous soft tissue over the malar regions bilaterally and some associated skin thickening noted in this region. Findings suggest inflammatory or post-traumatic process such as cellulitis/fasciitis or hematoma, bilaterally. Differential concerns, though remote, would include non-Hodgkin's lymphoma or changes from facial soft tissue augmentation procedures. Masticator spaces are unremarkable bilaterally and no muscle involvement currently identified.

Salivary glands: The parotid glands and submandibular glands have an unremarkable imaging appearance.

Orbit & globes: Soft tissues swelling extends to the inferior margin of the orbit, anteriorly. The post septal orbital soft tissues are otherwise unremarkable. Lacrimal glands are unremarkable. Globes are unremarkable.

Paranasal sinuses and mastoid air cells: Paranasal sinuses are normally aerated.

Visualized intracranial structures: The visualized intracranial structures are within normal limits.

Skull bases and cervical spine: The skull base and partially visualized upper cervical spine are intact and unremarkable.

Surgical Pathology Report*:

Pathologic diagnosis

“Upper lip, incisional biopsy: Dermal acute and chronic granulomatous inflammation with pronounced giant-cell reaction; no evidence of malignancy.”

*Upon receipt of this surgical pathology Report, the ENT requested another review of the biopsy slides by a second pathologist.

Pathology Report Addendum [Table 2]:

Interpretation/Result

“The slides show an incisional biopsy of oral mucosa with well-formed granulomata palisading around pale blue to gray areas of necrobiosis, with a few eosinophils in the necrobiotic foci. Small lymphocytes and histiocytes surround the granulomata. No Birefringent foreign material is identified on polarized light microscopic examination. No obvious needle-shaped clefts are identified in the necrobiotic areas. Dr. _____ was contacted by telephone, and there is no known history of injected collagen or other substance [previous history of Juvéderm Voluma injection was not disclosed, yet]. The well-formed granulomata and necrobiosis would be unusual for granulomatous cheilitis, although this remains a possibility, as does a reaction to non-birefringent foreign material or endogenous material, and other granulomatous processes. It is unclear how to best classify this granulomatous inflammatory pattern. This case will be sent for review to UCSF Dermatopathology and Oral Pathology Service, and the result will be issued as an addendum to this report.

A literature search on adverse effects of dermal fillers by the patient's former dentist in Chicago, led to a working diagnosis of a foreign body reaction to hyaluronic acid dermal fillers. Following contact and case discussion between the patient's plastic surgeon and the medical consultant for the Allergan Corp, an adverse reaction to Juvéderm Voluma was identified as a probable etiology for the facial Granulomatosa. A series of hyaluronidase injections were prescribed as a treatment and administered to the patient by her plastic surgeon. Six weeks following the initiation of hyaluronidase injections, the patient's facial swelling subsided and is no longer visible [Figure 4].

Discussion

This patient scenario presents a number of confounding obstacles for obtaining a proper diagnosis and potential treatment. The first obstacle was the patient presenting a diagnostic dilemma for facial edema with unknown etiology. Within the diagnostic thinking process of various pathologic causes for facial edema, multiple healthcare providers initially considered a number of entities in the development of a differential diagnosis [Figure 5]. The patient's past history, current health status, localization of the edema, absence of any signs or symptoms of infectious agents, autoimmune disease, or neoplasm led to the following differential diagnosis:

- Orofacial Granulomatosis

- Allergy
- Foreign Body Reaction

Allergy as an etiology was ruled out following examination of the patient by an allergist. The lack of a proper history regarding dermal filler injections made the consideration of a foreign body reaction to be unlikely. Orofacial granulomatosis is an uncommon disease encompassing a variety of clinical presentations, when biopsied; reveal the presence of nonspecific granulomatous inflammation. [5] Orofacial swelling, with or without intraoral manifestations is a common presentation at onset. [6] The disorder is idiopathic but appears to represent an abnormal immune reaction to a variety of inciting agents. Orofacial granulomatosis is highly

variable and can occur at any age; however, the majority of patients are adults. The most frequent site of involvement is the lips. The labial tissues demonstrate a nontender, persistent swelling that may involve one or both lips. When involving the lips alone, it is called Chelitis Granulomatosa. In addition, similar lesions can be seen in association with a number of systemic diseases, such as Sarcoidosis and Crohn's. [8] The pathologic examination in this case demonstrated well-formed granulomata and necrobiosis which are not the type of granulomas seen classically with chelitis granulomatous. A literature search on Pub Med, using search terms-Foreign Body, Granulomas, Dermal Fillers, Hyaluronic Acid Fillers-found a number of studies reporting genuine granuloma formation following implantation of injectable dermal fillers as a rare complication. Reported incidences ranged from one in 100 patients (1 percent) to one in 5000 (0.02 percent). Foreign body granulomas have been observed several months to years after injection at implantation sites [9-11].

In the era of evidenced-based practice and technological advances, taking a proper medical history often has been underrated in its efficacy in the diagnostic process. This idea continues to be contrasted with the traditional method of thorough history taking, physical examination, and clinical reasoning about what tests, if any, are needed to reach a proper diagnosis. The later tradition in medicine may take somewhat longer, but remains a cornerstone of clinical practice. [2, 3] In this current scenario, knowledge of the dermal fillers and Botox injections was not ascertained in history-taking from each of the healthcare providers that examined the patient. The patient's history of treatment by a plastic surgeon, one year prior to the onset of facial edema, remained unknown. A further obstacle to obtaining a proper diagnosis in this case could be the lack of a common medical record. If each Medical Record contains sufficient, accurate information that could be used to support a diagnosis and justify treatment, patient outcomes would promote continuity of care among health care providers. [4] In this particular case, the previous treatment



Figure 4: Resolution of facial swelling following hyaluronidase injections.

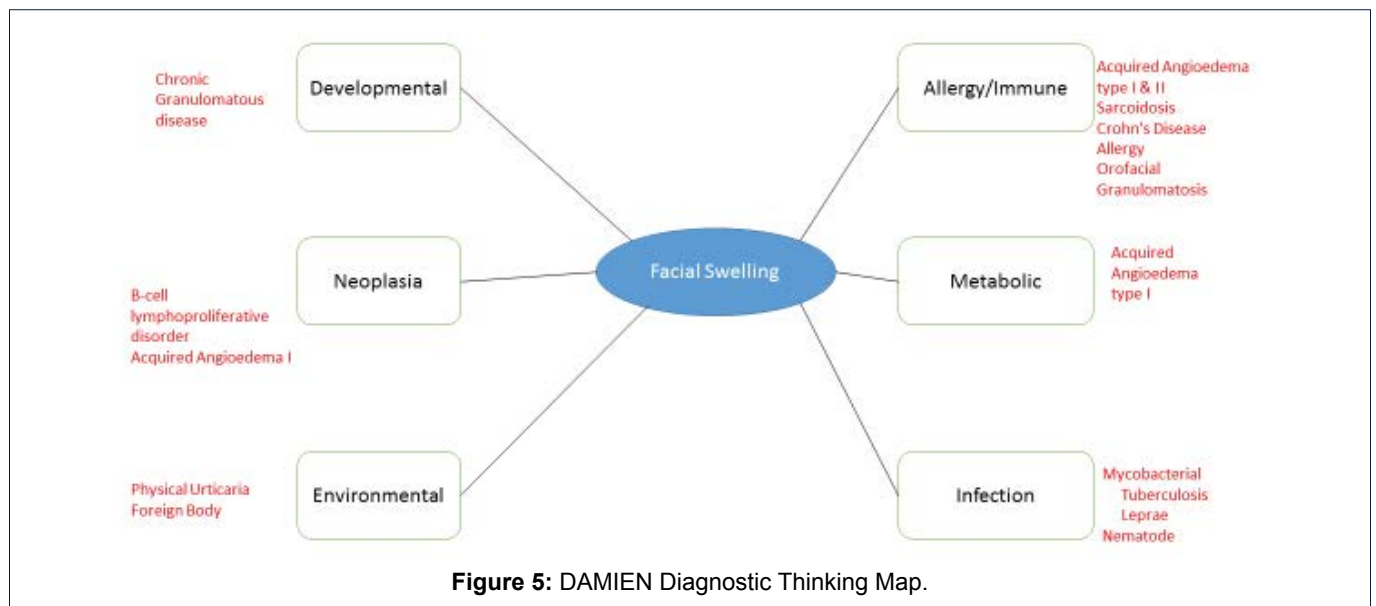


Figure 5: DAMIEN Diagnostic Thinking Map.

record from the patient's plastic surgeon would have been available and of consideration in the diagnostic process and subsequent resolution of the facial granulomatosis.

References

1. Mignogna MD, Fedele S, Lo Russo L, Lo Muzio L (2003) The multiform and variable patterns of onset of orofacial granulomatosis. *J Oral Pathol Med* 32: 200-205. [[View Article](#)]
2. Del Mar C, Glasziou P (2003) How many conditions can a GP screen for? *BMJ* 327: 1117. [[View Article](#)]
3. Hampton JR, Harrison MJG, Mitchell JRA, Prichard JS, Seymour C (1975) Relative contributions of history taking, physical examination, and laboratory investigation to diagnosis and management of medical outpatients. *Br Med J* 2: 486-489. [[View Article](#)]
4. Hayrinen K, Saranto K, Nykanen P (2008) Definition, structure, content, use and impacts of electronic health records: A review of the research literature. *Int J Med Inform* 77: 291-304. [[View Article](#)]
5. Tilakaratne WM, Freysdottir J, Fortune F (2008) Orofacial granulomatosis: review on aetiology and pathogenesis. *J Oral Pathol Med* 37: 191-195. [[View Article](#)]
6. Al Johani K, Moles DR, Hodgson T, Fedel, SR (2009) Onset and progression of clinical manifestations of orofacial granulomatosis. *Oral Dis* 15: 214-219. [[View Article](#)]
7. Al Hamad A, Porter S, Fedele S (2015) Orofacial Granulomatosis. *Dermatol Clin* 33: 433-436. [[View Article](#)]
8. Neville BW, Damm DD, Allen CM, Chi AC (2016) *Oral and Maxillofacial Pathology* 4th edn. St. Louis, Mo: Elsevier, USA, pp. 1-928. [[View Article](#)]
9. Lee JM, Kim Y (2015) Foreign body granulomas after the use of dermal fillers: pathophysiology, clinical appearance, histological features, and treatment. *Arch Plast Surg* 42: 232-239. [[View Article](#)]
10. Gutowski KA (2016) Hyaluronic Acid Fillers. *Clin Plastic Surg* 43: 489-496. [[View Article](#)]
11. Yang JH, Lee SM, Won CH, Chang SE, Lee MW, et al. (2012) Foreign body granuloma caused by hyaluronic acid / dextranomer microspheres filler injection. *Int J Dermatol* 51: 1517-1518. [[View Article](#)]

Citation: Brown BP (2018) Orofacial Granulomatosa: A Case for Interprofessional Collaboration. *Dent Pract* 1: 001-005.

Copyright: © 2018 Brown BP. This is an open-access article distributed under the terms of the Creative Commons Attribution License, which permits unrestricted use, distribution, and reproduction in any medium, provided the original author and source are credited.